ID Design 2012/DOOEL Skopje, Republic of Macedonia
South East European Journal of Immunology
Volume 2015; Article ID 20005, 4 pages
http://dx.doi.org/10.3889/seejim.2015.20005
***Case Report***

# Late Diagnosis of Takayasu Arteritis with Cardiac Involvement: Case Report

Maja Stojanović[1*], Aleksandra Perić-Popadić[1,2], Sanvila Rašković[1,2], Jasna Bolpačić[1,2], Maja Vučković[3], Vesna Tomić Spirić[1,2], Mirjana Bogić[1,2]

*[1]Clinic of Allergology and Immunology, Clinical Center of Serbia, Belgrade, Serbia; [2]Medical Faculty, University of Belgrade, Belgrade, Serbia; [3]Center of Radiology and Magnetic resonance, Clinical Center of Serbia, Belgrade, Serbia*

**Citation:** Stojanović M, Perić-Popadić A, Rašković S, Bolpačić J, Vučković M, Tomić Spirić V, Bogić M. Late Diagnosis of Takayasu Arteritis with Cardiac Involvement: Case Report. SEE J Immunol. 2015 Dec 31; 2015:20005. http://dx.doi.org/10.3889/seejim.2015.20005

**Key words:** Takayasu arteritis; heart failure; systemic vasculitis; fever of uknown origin.

[*]**Correspondence:** Maja Stojanović. Clinic of Allergy and Immunology, Clinical Center of Serbia, Kosta Todorovic Street 2, Belgrade, Serbia. Telephone number +381 11 3663700; Mobile +381 63 306216. E-mail: dr.maja.stojanovic@gmail.com

**Received:** 04-Nov-2015; **Revised:** 02-Dec-2015; **Accepted:** 30-Dec-2015; **Published:** 31-Dec-2015

**Copyright:** © 2015 Maja Stojanović, Aleksandra Perić-Popadić, Sanvila Rašković, Jasna Bolpačić, Maja Vučković, Vesna Tomić Spirić, Mirjana Bogić. This is an open-access article distributed under the terms of the Creative Commons Attribution-NonCommercial 4.0 International License (CC BY-NC 4.0).

**Competing Interests:** The author have declared that no competing interests exist.

**Abstract**

Takayasu arteritis (TA) is an idiopathic chronic granulomatous vasculitis that affects aorta, its main branches and occasionally pulmonary arteries. It is more common in Asian persons, affecting predominantly young women. Clinical presentation is nonspecific at the beginning of the disease, while in the ischemic disease's stage it depends on the territories affected. We present the case of a 26-year-old woman who was diagnosed as having TA. Multiple vascular abnormalities of aorta and its branches and severely reduced left ventricular function were present at the time of diagnosis. Immunosuppressive treatment consisting of prednisone and azathyoprine along with conventional heart failure therapy significantly improved her cardiac function.

## Introduction

Takayasu arteritis (TA) is an idiopathic chronic granulomatous vasculitis that affects aorta, its main branches and occasionally pulmonary arteries [1]. TA is known worldwide with an estimated incidence of 1.2-2.6/million per year in the western population and is seen in all races, but the incidence is higher in Southeast Asia, Central and South America, and Africa [2]. Clinical presentation is nonspecific at the beginning of the disease with possible fever, malaise, anorexia, myalgia, joint pain. Months to years later, in the pulseless phase, symptoms such as limb claudication, abdominal pain, neurological manifestations or visual disturbances due to end-organ ischemia appear [3]. Clinically, decreased or absent peripheral pulses, arterial bruits and systemic arterial hypertension can be found [4]. Although the pattern of disease varies geographically, stenotic lesions that are found in 90% of patients predominate; aneurysms are reported in approxymately 25%, while cardiac involvement is considered to be rare [5].

The aim of this report was to present the case of a 26-year-old woman who was diagnosed as having TA.

## Case report

A 26-year-old woman was admitted at our institution in October 2012. She was complaining of

malaise, shortness of breath, paroxysmal chest pain, subfebrile temperature, night sweats and weight loss of 10 kg over a period of one year. Her symptoms progressed over the course of two years. On examination, the patient was pale, without significant lymphadenopathy and detectable joints swelling. Chest auscultation revealed a loud pansystolic murmur throughout the precordium. Bruits were evident over both common carotid arteries, more so over the right. A significant clinical finding included a diminished left radial pulse compared to the right. Blood pressure measured on both arms was slightly elevated (140/90 mm Hg), but was not significantly asymmetric. Routine laboratory results revealed a raised erythrocyte sedimentation rate (ESR) and C-reactive protein (CRP) at 105 mm/h and 103 mg/L, respectively.

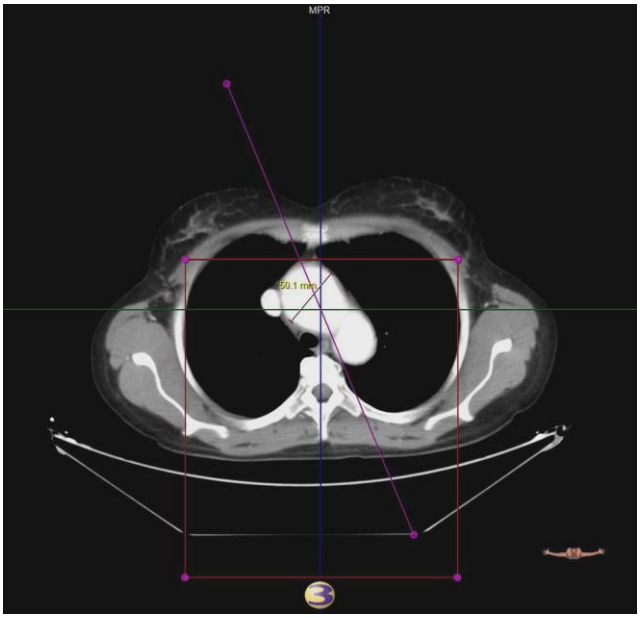


*Figure 1: CT angiography shows axial view of the aorta; concentric mural thickening and aneurismatic dilatation of the ascending aorta was found*

Immunological tests including antinuclear, anti-neutrophil cytoplasmic, anti citric citullinated peptide, anticardiolipin, and anti beta 2 glycoprotein antibodies, rheumatoid factor, complement fractions and cryoglobulins were all negative. Protein electophoresis revealed an elevated gamma globuline fraction (28.8% of total proteins) and immunoglobuline G (21 g/l) with a normal fraction of IgG4 subclass. Sputum studies for acid fast bacilli and PPD test for tuberculosis were negative. Treponema Pallidum Haemagglutination assay was negative. No positive laboratory markers for sarcoidosis were found. A transthoracic heart Doppler ultrasound revealed a medium grade aortic regurgitation and left ventricular enlargement with a severe impairement of systolic function with ejection fraction of 30% (EF of 55 percent or higher is considered normal). A poorly contractile heart with features typical to dilatative cardyomyopathy was demonstrated; a larger ascending aortic diameter and a thickened aortic wall up to 8 mm in particular places, initially suspected to aortic dissection were seen (wall thickness up to 4 mm is regarded normal). Carotid Dopplers revealed high-grade stenoses at the bifurcation of both common carotid artery, significant wall thickening in both subclavian arteries, with a severely diminished flow on the left. A computed tomography arteriogram revealed multiple stenosis and dilatations of the aortic arch, ascending and descending aorta with features of arteritis in the wall. The most prominent dilatation, with a transversal diameter of 50 mm, was seen at the ascending aorta (Figure 1) and the most striking stenosis was observed in the middle of the descending aorta (Figure 2). Most of the main branches of aorta appeared irregularly shaped, but narrowing of the renal arteries was not present.

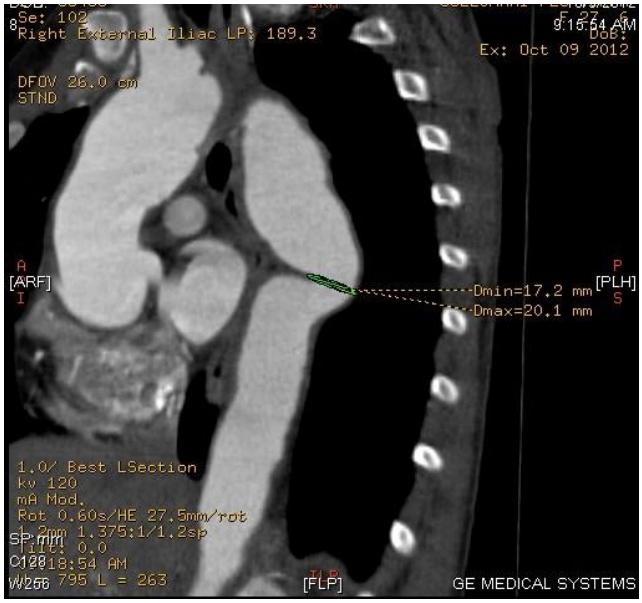


*Figure 2: CT angiography shows sagital view; stenosis of the thoracic aorta up to 17,2mm was seen*

The patient fulfilled five of six necessary American College of Rheumatology (ACR) classification criteria for TA and the treatment by prednisolone of 1 mg per kilogram per day was started. After two weeks of therapy, an improvement of inflammatory signs was noticed. Her constitutional symptoms disappeared with the resolution of inflammatory markers. Additionally, therapy consisting of enalaprile, amlodipine, hydrochlorthiazide, spironolactone and aspirin was suggested. Few weeks later, Azathioprine 100mg per day was administered along with gradually reduction of prednisone. Median levels of ESR, CRP, diminished to 18 mm/h and 3.0 mg/l, respectively. On a follow up visit, six months later, all laboratory tests were within normal range. Her cardiac function was significantly improved, and an estimated EF of 50% was measured.

## Discussion

Takayasu's arteritis is a systemic inflammatory disease of unknown etiology [1]. It is more common in Asian persons, affecting predominantly young women [6]. TA is a panarteritis mediated by T lymphocyte, monocyte and macrophage that infiltrate arterial wall, leading to marked intimal myofibroblast proliferation and fibrosis of the media and adventitia [7]. The disease has a biphasic course. The early systemic or 'pre-pulseless' phase is characterized by active inflammation and nonspecific signs and symptoms, including fever, malaise, anorexia, weight loss, carotidynia, myalgia and arthralgia [3]. During the course of the disease, manifestations such as hypertension, bruits, headaches, postural dizziness, and syncope may appear. Clinical presentation in the late or 'pulseless' phase is largely dependent upon the site and grade of arterial lesion [8]. In 1990, the ACR proposed classification criteria for diagnosis of TA: age of disease onset < 40 years, claudication of extremities, decreased brachial artery pulse, blood pressure difference > 10 mmHg, bruit over subclavian arteries or aorta, arteriogram abnormality. The presence of 3 or more of these 6 criteria demonstrated a sensitivity of 90.5% and a specificity of 97.8% in diagnosis of TA [9]. Moreover, although diagnostic criteria exist, patients presenting with early pre–stenotic disease may not fulfil them [10]. For that reason, the delay in diagnosis from initial manifestation of the disease can be 2–11 years in adults and sometimes longer in children [11]. This is complicated by the lack of specific laboratory markers including autoantibodies [12]. Some patients develop cardiac abnormalities, that are, generally regarded, consequence of hypertension, pulmonary vascular involvement, coronary artery disease and aortic regurgitation. However, in some cases, the left ventricule dysfunction was documented without associated hypertension, valvular lesion or coronary artery disease [13]. Talwar et al reported that combined therapy of prednisolone and cyclophosphamide over 12 weeks improved not only clinical and hemodynamic state, but also myocardial morphology of patients with Takaysu myocarditis [14]. These findings strongly suggest that immunological processes play a significant role in TA related myocarditis [13]. According to the recent study of Yang et al, hypertension, major complications, and a progressive disease course are statistically significant predictors of 5-years survival [15].

Aortic lesions are often associated with aortitis in several divergent etiologies such as connective tissue diseases, infective and IgG4-related sclerosing aortitis [16, 17].

The rarity of TA and the heterogeneous nature of the possible clinical manifestations often lead to a late diagnosis and delayed treatment. Nazareth et al., tried to facilitate this suggesting 'red flags symptoms' that should alert the physician to the possibility of TA. In their cohort of 68 patients, 91% displayed one or more red flag symptoms: carotidynia, angina, limb claudication, absent or weak peripheral pulses, hypertension discrepant blood pressure in the upper limbs (> 10 mmHg), arterial bruits, aortic regurgitation or non explained acute-phase response, such as elevated ESR or CRP [4].

The mainstay in the treatment of TA is glucocorticosteroids (gks) for induction of remission and for maintenance in low doses up to 1 to 2 years. However, the risk of relapse following gks withdrawal is high and gks-sparing drugs including methotrexate or azathyoprine are often recommended [18]. Pulsed intravenous cyclophosphamide is reserved for those with life-threatening disease or failing to respond to first-line treatments [19]. Recent reports suggest that patient refractory to conventional therapy might respond to tumor-necrosis factor or interleukin 6 blockers [20]. Treatment of hypertension and prevention of thrombosis are also important aspects of therapy [21].

In our case, gks administration, in conjunction with an additional immunosuppressant and conventional heart failure therapy dramatically restored left ventricular systolic function. These findings suggest that cytotoxic mechanisms similar to those in the walls of vessel affected, may also contribute to cardiac involvement in certain patients with Takayasu arteritis [13]. Surgery may be needed in patients with critical renal artery stenoses, limb claudication limiting the daily activities, stenosis of three or more cerebral vessels and moderate aortic regurgitation [22].

Assessing disease activity in TA is challenging as there is frequently a lack of clinical and investigational correlation. New onset or worsening of two or more of the criteria of TA are indicative of disease exacerbation [6], though angiographic disease progression and histological progression can be seen even during an inactive phase of the disease. A similar situation is faced with the assessment of laboratory markers such as ESR and several other acute phase reactants. Recent investigations have focused on identification of novel and sensitive biomarkers of the disease activity such as pentraxin-3 [23] and imaging techniques such as $^{18}$F-FDG PET/CT [24].

In conclusion, we emphasize the importance of the early diagnosis of TA, which can be difficult due to initial nonspecific symptoms and clinical presentation. The case presented above demonstrate the serious consequences associated with a delayed diagnosis, and propose that this might be prevented by increased clinical awareness of TA and early use of non-invasive imaging such as $^{18}$F-FDG PET/CT. Early treatment with gks and cytotoxic agents is important to avoid rapid progression of the vascular

lesions and may prevent irreversible cardiovascular complications.

## References


1. Johnston SL, Lock RJ, Gompels MM. Takayasu arteritis: a review. J Clin Pathol. 2002;55:481-6. http://dx.doi.org/10.1136/jcp.55.7.481 PMid:12101189 PMCid:PMC1769710

2. Richards BL, March L, Gabriel SE. Epidemiology of large-vessel vasculitides. Best Pract Res Clin Rheumatol. 2010;24:871-3. http://dx.doi.org/10.1016/j.berh.2010.10.008 PMid:21665132

3. Maffei S, Di Renzo M, Bova G, Auteri A, Pasqui AL. Takayasu's arteritis: a review of the literature. Intern Emerg Med. 2006; 1:105-12. http://dx.doi.org/10.1007/BF02936534 PMid:17111782

4. Nazareth R, Mason JC. Takayasu arteritis: severe concequences of delayed diagnosis. QJM. 2011;104:797-800. http://dx.doi.org/10.1093/qjmed/hcq193 PMid:20952441

5. Mason JC. Takayasu arteritis-advances in diagnosis and management. Nat Rev Rheumatol. 2010;6:406-15. http://dx.doi.org/10.1038/nrrheum.2010.82 PMid:20596053

6. Kerr GS, Hallahan CW, Giordano J, Leavitt RY, Fauci AS, Rottem M, Hoffman GS. Takayasu arteritis. Ann Intern Med. 1994;120:919-29. http://dx.doi.org/10.7326/0003-4819-120-11-199406010-00004 PMid:7909656

7. Johnston SL, Lock RJ, Gompels MM. Takayasu arteritis: a review. J Clin Pathol. 2002;55:481–6. http://dx.doi.org/10.1136/jcp.55.7.481 PMid:12101189 PMCid:PMC1769710

8. Park MC, Lee SW, Park YB, Chung NS, Lee SK. Clinical characteristics and outcomes of Takayasu's arteritis: Analysis of 108 patients using standardized criteria for diagnosis, activity assessment, and angiographic classification. Scand J Rheumatol. 2005;34:284-92. http://dx.doi.org/10.1080/03009740510026526 PMid:16195161

9. Arend WP, Michel BA, Bloch DA, Hunder GG, Calabrese LH, Edworthy SM, Fauci AS, Leavitt RY, Lie JT, Lightfoot RW Jr, et al. The American College of Rheumatology 1990 criteria for the classification of Takayasu arteritis. Arthritis Rheum. 1990;33:1129-34. http://dx.doi.org/10.1002/art.1780330811 PMid:1975175

10. Lambert M, Hatron PY, Hachulla E, Warembourg H, Devulder B. Takayasu's arteritis diagnosed at the early systemic phase: diagnosis with noninvasive investigation despite normal findings on angiography. J Rheumatol. 1998;25:376–7. PMid:9489837

11. Tann OR, Tulloh RM, Hamilton MC: Takayasu's disease: a review. Cardiol young 2008;18:250–9. http://dx.doi.org/10.1017/S1047951108002060 PMid:18325145

12. Hoffman GS, Ahmed AE. Surrogate markers of disease activity in patients with Takayasu arteritis. A preliminary report from The International Network for the Study of the Systemic Vasculitides (INSSYS). Int J Cardiol. 1998;66(Suppl. 1):S191–4. http://dx.doi.org/10.1016/S0167-5273(98)00181-8

13. Takeda N, Takahashi T, Seko Y, Maemura K, Nakasone H, Sakamoto K, Hirata Y, Nagai R. Takayasu myocarditis mediated by cytotoxic T lymphocytes. Intern Med. 2005;44:256-60. http://dx.doi.org/10.2169/internalmedicine.44.256 PMid:15805718

14. Talwar KK, Chopra P, Narula J, Shrivastava S, Singh SK, Sharma S, Saxena A, Rajani M, Bhatia ML. Myocardial involvement and its response to immunosuppressive therapy in nonspecific aortoarteritis (Takayasu's disease) a study by endomyocardial biopsy. Int J Cardiol. 1988;21:323–334. http://dx.doi.org/10.1016/0167-5273(88)90109-X

15. Yang L, Zhang H, Jiang X, Zou Y, Qin F, Song L, Guan T, Wu H, Xu L, Liu Y, Zhou X, Bian J, Hui R, Zheng D. Clinical manifestations and longterm outcome for patients with Takayasu arteritis in China. J Rhumatol. 2014;41:2439-2446. http://dx.doi.org/10.3899/jrheum.140664 PMid:25274886

16. Kasashima S, Zen Y, Kawashima A, Endo M, Matsumoto Y, Kasashima F, Ohtake H, Nakanuma YJ. A clinicopathologic study of immunoglobulin G4-related sclerosing disease of the thoracic aorta. Vasc Surg. 2010;52:1587-1595. http://dx.doi.org/10.1016/j.jvs.2010.06.072 PMid:20678882

17. Maksimowicz-McKinnon K, Clark TM, Hoffman GS. Limitations of therapy and a guarded prognosis in an American cohort of Takayasu arteritis patients. Arthritis Rheum. 2007;56:1000–9. http://dx.doi.org/10.1002/art.22404 PMid:17328078

18. Kotter I, Henes JC, Wagner AD, Loock J, Gross WL. Does glucocorticosteroid-resistant large-vessel vasculitis (giant cell arteritis and Takayasu arteritis) exist and how can remission be achieved? A critical review of the literature. Clin Exp Rheum. 2012;30:S114-129. PMid:22640655

19. Clifford A, Hoffman GS. Resent advances in the medical management of Takayasu arteritis: un update on use biologic therapies. Curr Opin Rheumatol. 2014;26:7-15. http://dx.doi.org/10.1097/BOR.0000000000000004 PMid:24225487

20. Isobe M. Takayasu arteritis revisited: current diagnosis and ttreatment. Int J Cardiol. 2013;168:3-10. http://dx.doi.org/10.1016/j.ijcard.2013.01.022 PMid:23415176

21. Giordano JM. Surgical treatment of Takayasu's Arteritis. Int J Cardiol. 2000;75:S123-28. http://dx.doi.org/10.1016/S0167-5273(00)00179-0

22. Dagna L, Salvo F, Tiraboschi M, Bozzolo EP, Franchini S, Doglioni C, et al. Pentraxin-3 as a marker of disease activity in Takayasu's arteritis. Ann Intern Med. 2011;155:425-433. http://dx.doi.org/10.7326/0003-4819-155-7-201110040-00005 PMid:21969341

23. Yamashita H, Kubota K, Mimori A. Clinical value of whole-body PET/CT in patients with active rheumatic diseases. Arthritis Res Ther. 2014;16:423-35. http://dx.doi.org/10.1186/s13075-014-0423-2 PMid:25606590 PMCid:PMC4289312

24. Santhosh S, Mittal BR, Gayana S, Bhattacharya A, Sharma A, Jain S. F-18FDG PET/CT in the evaluation of Takayasu arteritis: an experience from the topics. J Nucl Cardiol. 2014;21:993-1000. http://dx.doi.org/10.1007/s12350-014-9910-8 PMid:24875577