Scientific Foundation SPIROSKI, Skopje, Republic of North Macedonia
South East European Journal of Immunology. 2024 Jan 23; 7(1):7-12.
https://doi.org/10.3889/seejim.2024.6060
eISSN: 1857-9388
Category: *Case Report*
Section: *Clinical Immunology*

OPEN ACCESS

Drug Rash with Eosinophilia and Systemic Symptoms Syndrome: Case Report and Literature Review

Silvija Duma[1]*, Suzana Nikolovska[1], Hristian Duma[2], Hristina Breshkovska[1], Ivana Dohcheva Karajovanov[1], Maja Dimova[1], Ana Trpeska-Boshoska[2]

[1]University Clinic of Dermatology, University Ss Cyril and Methodius, Skopje, Republic of North Macedonia; [2]University Clinic of Ophthalmology, University Ss Cyril and Methodius, Skopje, Republic of North Macedonia

Edited by: Slavica Hristomanova-Mitkovska
Citation: Duma S, Nikolovska S, Duma H, Breshkovska H, Karajovanov ID, Dimova M, Trpeska-Boshoska A. Drug Rash with Eosinophilia and Systemic Symptoms Syndrome: Case Report and Literature Review. South East Eur J Cardiol. 2024 Jan 23; 7(1):7-12. https://doi.org/10.3889/seejim.2024.6060
Keywords: DRESS syndrome; Idiosyncratic drug reaction; Allopurinol; Case Report
***Correspondence:** Silvija Duma, University Clinic of Dermatology, University Ss Cyril and Methodius, Skopje, Republic of North Macedonia.
E-mail: drsduma@yahoo.com
Received: 06-Nov-2023
Revised: 09-Dec-2023
Accepted: 05-Jan-2024
Copyright: © 2024 Silvija Duma, Suzana Nikolovska, Hristian Duma, Hristina Breshkovska, Ivana Dohcheva Karajovanov, Maja Dimova, Ana Trpeska-Boshoska
Funding: This research did not receive any financial support
Competing Interests: The authors have declared that no competing interests exist
Open Access: This is an open-access article distributed under the terms of the Creative Commons Attribution-NonCommercial 4.0 International License (CC BY-NC 4.0)

Abstract

BACKGROUND: Drug Reaction with Eosinophilia and Systemic Symptoms (DRESS) Syndrome is a rare, potentially life-threatening, drug-induced hypersensitivity reaction. This condition is characterized by a range of symptoms, including cutaneous reaction, hematologic abnormalities, lymphadenopathy, and potential involvement of internal organs. Most DRESS cases are associated with certain medications such as antiseizure drugs, allopurinol, antibacterial sulfonamides, minocycline, and vancomycin.

CASE PRESENTATION: We presented a case of 70-year-old women exhibiting maculopapular rash affecting the face, abdomen, and extremities. She experienced generalized pruritus, along with ulcerative crusty lesions on the mouth and mucopurulent conjunctivitis, all of which had persisted for 1 week. She was recently diagnosed with hyperuricemia and had been undergoing treatment with allopurinol for 4 weeks. During her hospital stay, the rash intensified, and there was a worsening involvement of the mucosa in the oral and ocular area. Allopurinol was promptly discontinued, and the patient was prescribed a daily dose of 100 mg prednisolone, gradually tapering off over a 2-month period. Additionally, the treatment included anticoagulants, antibiotics, local application of mild steroid emulsions, antiseptic, and antifungal therapy for the oral mucosa. Antibiotic solutions and natural tear eye drops were used. Over the 2-month period, the rash completely resolved, and the liver enzymes returned to normal levels.

CONCLUSION: DRESS syndrome is an unpredictable drug-induced reaction identified by symptoms such as rash, fever, lymphadenopathy, and potential internal organ involvement. Allopurinol is among the medications associated with this condition, particularly when there is a reduced renal clearance and simultaneous use of thiazide diuretics. Prompt withdrawal of the causative drug is the universally accepted approach to manage drug-induced hypersensitivity reactions. The use of systemic corticosteroids can reduce symptoms of delayed hypersensitivity reactions. However, the absence of randomized controlled trials leaves uncertainty about the necessity of administering steroids, sparking a controversial debate regarding their use in such cases.

Introduction

Drug Reaction with Eosinophilia and Systemic Symptoms (DRESS) Syndrome is a rare, potentially life-threatening, drug-induced hypersensitivity reaction characterized by a cutaneous eruption, hematologic abnormalities, lymphadenopathy, and/or internal organ involvement [1]. Literature data show that the accurate incidence of this condition remains uncertain, as a significant number of cases may not have been diagnosed due to the varying clinical presentations, diverse features, and laboratory abnormalities. However, the estimated reported that frequency of DRESS has been approximated to be more than 1 occurrence/10,000 instances of exposure to anticonvulsants like carbamazepine [2]. Although there is a suggestion that the incidence of DRESS might be highest among elderly black men, the presence of a genuine racial predisposition is still uncertain [3]. There is a common agreement in many reports that DRESS does not show a specific age or sex preference. However, some studies have observed a slight tendency toward females. Moreover, the median age at diagnosis is around 51.4 years for men and 55.7 years for women, with ages ranging from 0 to 83 years [4], [5].

The pathogenesis of DRESS remains not entirely understood and is likely multifactorial, encompassing immunological mechanisms and specific drug detoxification pathways. Most of the DRESS cases are attributed to antiseizure medications, allopurinol, antibacterial sulfonamides, minocycline, and vancomycin [6]. In the majority of patients, the reaction begins 2–8 weeks after starting the triggering medication. The skin reaction initially appears as a maculopapular eruption that might evolve into a coalescing erythema. Other observed manifestations include purpura, infiltrated plaques, pustules, exfoliative dermatitis, and target-like lesions [7].

Systemic symptoms commonly observed in patients with DRESS encompass fever, lymphadenopathy, hematologic abnormalities (e.g. leukocytosis, eosinophilia, neutrophilia, and atypical lymphocytosis), accompanied by signs and symptoms indicative of

visceral involvement in one or multiple organs [8]. The most frequently observed complication in this condition is liver injury, affecting up to 90% of cases, which increases the risk of reported mortality [9]. Additionally, individuals may experience acute interstitial nephritis and interstitial pneumonia, with myocarditis being a less frequent occurrence [2]. DRESS cases mortality, which depends on patient age, existing health conditions, and the specific drug implicated, can reach up to 10% among patients and is frequently associated with undetected myocarditis and complications from cytomegalovirus (CMV) [7].

The diagnosis of DRESS is based on a combination of clinical manifestations (including skin-related symptoms and systemic signs), patient history involving recent exposure to drugs and, particularly high-risk medications within the previous 2–8 weeks, as well as laboratory and imaging results. The criteria used to confirm or exclude the diagnosis of DRESS are outlined in the Registry of Severe Cutaneous Adverse Reactions scoring system [4].

The primary focus of treatment for individuals with DRESS involves identifying and withdrawal of the causative drug, alongside providing supportive care. It is essential to conduct regular monitoring for potential organ involvement to ensure comprehensive management.

Case Report

A 70-year-old woman presented at the University Clinic of Dermatology, University Ss Cyril and Methodius, Skopje, Republic of North Macedonia exhibiting a maculopapular rash affecting her face, abdomen, and extremities, accompanied by generalized pruritus. Additionally, she exhibited an ulcerative and crusted lesion in her mouth, along with mucopurulent conjunctivitis that had been ongoing for 1 week (Figure 1). Informant consent was obtained from the patient to capture photographs.

The patient was recently diagnosed with hyperuricaemia and had been undergoing treatment with allopurinol for 4 weeks. Additionally, she has a medical history of cardiac arrhythmia and arterial hypertension, managed with atenolol and thiazide diuretics for several years. During the admission's physical examination, the temperature was 36.8°C. Furthermore, there were no indications of lymphadenopathy or hepatosplenomegaly detected. Initially, we conducted all necessary blood tests required for an accurate diagnosis. The results detailing hematologic and enzyme statuses are shown in Table 1. Protein, lipid, and electrolyte panels

Table 1: Comparison between the test results from three specific dates (08.08.2023, 11.08.2023, and 25.08.2023) for each specific test, alongside their respective reference ranges, facilitating a clearer comparison

Test	Results (08.08.2023)	Results (11.08.2023)	Results (25.08.2023)	Reference Range
Hematologic Status				
ESR	20	7	1	Female <50 y: 4–20, >50 y: 4–30; Male <50 y: 4–15, >50 y: 4–20
RBC	4.88	4.95	3.79	4.20–5.50×10^12/L
HGB	141	143	111	120–180 g/L
HCT	0.403	0.396	0.317	0.37–0.54 rv
MCV	82.5	80	83.8	82.0–98.0 fL
MCH	29	28.9	29.3	27.0–33.0 pg
MCHC	35.1	36.1	34.9	32.0–36.0 g/dL
RDW-SD	63.7	42.1	68.5	37.0–54.0 fL
RDW-CV	13.9	15.1	14.9	11.0–16.0%
WBC	6.5	8.83	12.1	4.00–9.00×10^9/L
LYMH	15.7	8	14.1	15–50%
MXD	5.2	/	6.8	2–15%
NEUT	79.1	82.7	79.1	35–80%
LYMPH_N	1	0.71	1.7	0.5–5.0×10^9/L
MXD_N	0.3	/	0.8	0.1–1.5×10^9/L
NEUT_N	5.2	7.3	9.6	1.2–8.0×10^9/L
PLT	250	239	67	150–450×10^9/L
PDW	13.3	14.8	16.8	9.0–17.0 fL
MPV	10.3	12	11.9	9.0–13.0 fL
P-CLR	28.5	40.2	44.8	13.0–43.0%
MONO	/	8.7	/	0.0–14.0%
BASO	/	0	/	0.0–1.0%
EO	/	0.6	/	0.0–6.0%
CRP	67.22	15.30	3.68	<6 mg/L
Enzyme Status (Serum)				
ALT	159	112	33	10–45 U/L
AST	141	50	18	10–34 U/L



Figure 1: The patient presents a noticeable maculopapular rash, notably affecting prominent areas such as the face (a), chest (b), extremities (c and d), and the abdomen (not shown). The rash appears to be widespread and displays a combination of flat, reddish areas (macules) and slightly raised, bumpy lesions (papules), indicating a diffuse skin involvement. Accompanying this rash, the patient appears to experience generalized itching (pruritus). Furthermore, the patient's oral cavity (a) shows an ulcerative and crusted lesion

conducted on the same dates were within the reference range (data not shown).

The initial urine analysis upon admission revealed the presence of erythrocytes, numerous epithelial cells, and a significant number of bacteria. Additionally, the viral markers (anti-HCV for hepatitis C and anti-HBs for hepatitis B) showed normal results. Furthermore, the initial assessment indicated that the hormonal profile, apart from parathyroid hormone, fell within normal ranges.

The coagulation profile test (Table 2) revealed heightened D-dimer levels, signaling a pronounced secondary fibrinolysis. As a result, clexane therapy was recommended as part of the treatment plan.

Table 2: Comparison between the coagulation profile results from four specific dates (08.08.2023, 11.08.2023, 25.08.2023, and 04.09.2023) for each specific test, alongside their respective reference ranges, facilitating a clearer comparison

Test	Results (08.08.2023)	Results (11.08.2023)	Results (25.08.2023)	Results (04.09.2023)	Reference Range
Hct	38.8	39.9	32.3	31.2	35–50%
PLT	221	233	70	132	150–450×10^9/L
TT	20.2	32.2	20.9	21.5	16.1 (22) 24.1 s
aPTT	31.5	35.8	21.6	27.2	27.9 (33) 37.7 s
PT	11.9	11.9	11.7	11.3	9.8 (13) 14.2 s
D-Dimers	13027	4754	5225	926.1	0– 500 ng/mL

Furthermore, the conducted tests for serum pneumoslide IF immunoglobulin G and immunoglobulin M specific to *Chlamydia pneumoniae*, along with ultrasound of the abdomen, RTG Pulmo (chest X-ray), and echocardiogram, all resulted with normal results.

The histopathology findings indicated orthohyperkeratosis with focal parakeratosis in the corneal layer. The epidermis displayed moderate acanthosis throughout, with a mostly compact basal layer. While a focal lymphocytic inflammatory infiltrate touches the basal layer in some areas, there was no vacuole degeneration observed in these cells. Individual apoptotic basal keratinocytes were visible, and melanophages contain pigment. In the papillary dermis, a moderate lymphocytic inflammatory infiltrate surrounds the dermal blood vessels, while a sparse perivascular lymphocytic infiltrate was noted in the reticular dermis.

During the hospital stay, the rash intensified, and there was a worsening involvement of the mucosa in the oral and ocular areas. Allopurinol was promptly discontinued, and the patient was prescribed a daily dose of 100 mg prednisolone, gradually tapering over a span of 2 months. Additionally, anticoagulant therapy and antibiotics were administered. Locally, low-potency steroid emulsions, antiseptics, and antifungal treatments were applied to the oral mucosa, while antibiotic solutions and natural tear drops were used for the eyes. Over the course of 2 months, the rash completely resolved (Figure 2), and liver enzyme levels (Table 1) returned to normal range.

Discussion

DRESS is a severe adverse drug reaction marked by widespread skin rash, organ involvement, lymphadenopathy, eosinophilia, and atypical lymphocytosis. Its presentation varies widely, and the condition often persists despite stopping the causative drug. Typically emerging 2–8 weeks after drug initiation, its exact cause remains unclear. Some theorize that specific drugs trigger a hypersensitivity reaction, potentially linked to genetic variations affecting drug metabolism pathways, leading to the production and detoxification of active metabolites [10]. DRESS is classified as a T cell-mediated hypersensitivity reaction. While its precise pathogenesis is not entirely clear, it is believed to involve two primary mechanisms: A targeted immune response to the drug itself and the reactivation of human Herpesviridae, followed by an immune reaction against the virus [11]. The involvement of a drug-specific immune response in DRESS pathogenesis has been established through positive patch test results for certain causative drugs. Additionally, *in vitro* studies have revealed the presence of drug-specific CD4+ and CD8+ T cells that produce significant quantities of tumor necrosis factor-alpha and interferon-gamma [2], [12], [13]. Reactivation of viruses within the Herpesviridae family – such as HHV-6, HHV-7, Epstein–Barr virus, and CMV – is a recognized phenomenon linked to DRESS, observed in as many as 75% of affected patients [14], [15]. Among the viruses in this family linked to DRESS, HHV-6 stands out as the most prevalent, with reported reactivation occurring in 16–60% of cases. The variability in reported percentages may arise from differences in detection methodologies [16], [17]. In around 30% of cases, multiple sequential reactivations of herpesviruses have been noted. This reactivation pattern often mirrors observations seen in graft-versus-host disease. During the acute phase of DRESS, there is a notable increase in circulating activated T lymphocytes within both CD4+ and CD8+ subsets, bearing activation markers and exhibiting an altered repertoire of the antigen receptor. Additionally, an increase in regulatory T cells has been evidenced during this phase of DRESS [18], [19].

DRESS syndrome is commonly associated with aromatic anticonvulsants such as phenytoin, phenobarbital, and carbamazepine, as well as sulfonamides. Additionally, other drugs linked to this syndrome include allopurinol, captopril, ranitidine, minocycline, tuberculostatic drugs, and certain antiretroviral medications such as zalcitabine and nevirapine [20]. Symptoms typically begin with fever and a morbilliform macular rash that initially appears on the face, abdomen, and upper limbs, later becoming pruritic, particularly in the lower limbs. Subsequently, exfoliative dermatitis may develop as the lesions fade. In some cases, initial symptoms might manifest as facial

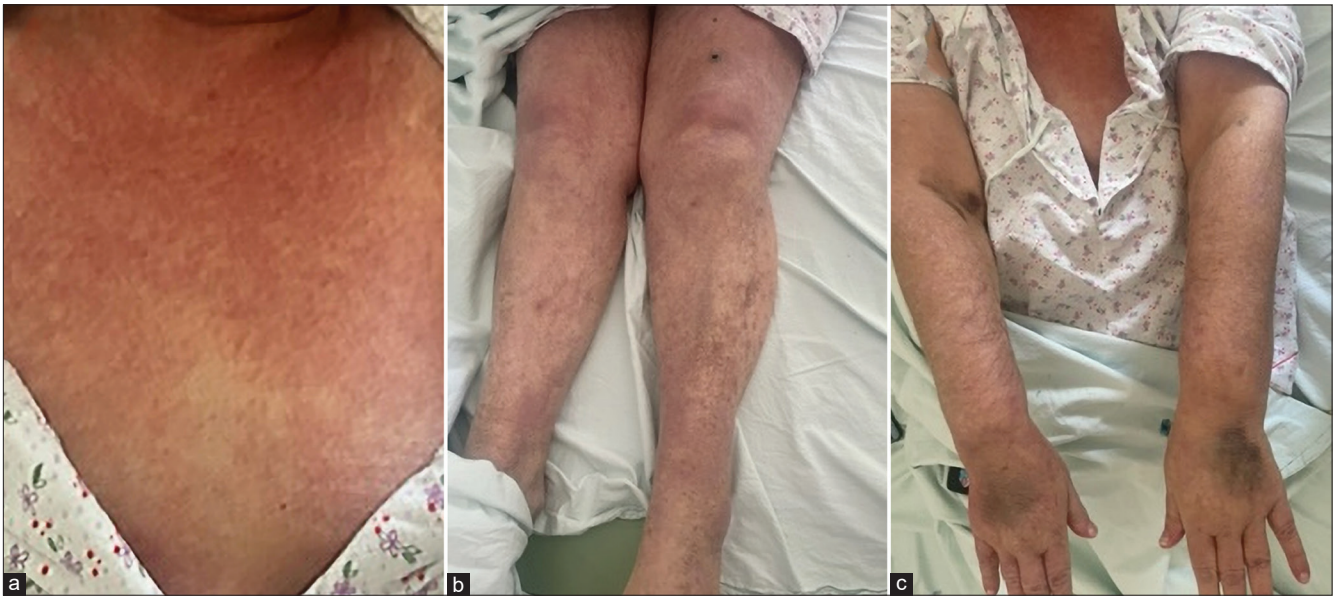

Figure 2: The patient demonstrates a significant improvement in the maculopapular rash, previously prominent on the chest (a) and the extremities (b and c)

edema, conjunctivitis, and erythema of the pharyngeal mucosa. The liver is commonly affected, leading to varied findings from transient increases in liver enzymes, as observed in our case, to severe complications such as liver necrosis and fulminant hepatic failure. Apart from liver involvement, DRESS syndrome can affect other organs such as the kidneys, lungs, and heart, leading to conditions such as interstitial nephropathy, pneumonitis, pericarditis, and myocarditis. In our case, myocarditis was suspected [21].

Allopurinol is among the implicated drugs in DRESS syndrome. The syndrome's onset is often linked to the accumulation of one of allopurinol's metabolites and oxypurinol. This accumulation becomes particularly significant in cases of reduced renal clearance and concurrent use of thiazide diuretics. While a skin biopsy might aid in confirming the diagnosis, it typically lacks specificity. The biopsy usually reveals a lymphocytic infiltrate in the papillary dermis, potentially containing eosinophils and appearing denser compared to other reactions. Differential diagnoses commonly considered alongside DRESS syndrome encompass conditions such as Stevens–Johnson syndrome (SJS), toxic epidermal necrolysis (TEN), hypereosinophilic syndrome, and Kawasaki disease [22], [23], [24].

DRESS reactions tend to occur more frequently in individuals with specific human leukocyte antigen (HLA) types. In these cases, drugs have demonstrated a pronounced tendency to bind with certain HLA alleles – predominantly in instances such as allopurinol/oxypurinol binding to HLA-B58:01 or exclusively as observed with abacavir and HLA-B57:01. This phenomenon, observed in both DRESS, SJS and TEN, underscores the role of HLA typing in predicting drug-induced hypersensitivity reactions [25]. Specific drug reactions, such as DRESS and SJS/TEN attributed to allopurinol, have been linked with the HLA-B*58:01 allele [14]. The association of B*58:01 with allopurinol-induced SJS/TEN is less prevalent in Caucasians, estimated at around 60%, as other alleles also play a role in these reactions. Moreover, DRESS and, in certain instances, SJS/TEN triggered by carbamazepine disproportionately affect various ethnic groups [26].

Once a patient has been identified as having a high-risk HLA profile, it is advisable to counsel their family members to avoid the relevant drug, as familial occurrences of similar hypersensitivity reactions have been observed. Screening recommendations have been proposed for specific alleles before administering drugs such as carbamazepine, oxcarbazepine, abacavir, and allopurinol [27].

Conclusion

DRESS syndrome stands as an idiosyncratic drug reaction marked by a distinctive set of symptoms including rash, fever, lymphadenopathy, and internal organ involvement. Allopurinol is among the drugs implicated, particularly in cases of reduced renal clearance and concurrent use of thiazide diuretics. Prompt discontinuation of the causative drug remains the indisputable approach for managing drug hypersensitivity reactions. While systemic corticosteroids may alleviate symptoms of delayed hypersensitivity reactions, the absence of robust randomized controlled trials has left the decision to administer steroids a subject of controversy.

References

1. Tas S, Simonart T. Drug rash with eosinophilia and systemic symptoms (DRESS syndrome). Acta Clin Belg. 1999;54(4):197-200.
   PMid:10544509
2. Shiohara T, Kano Y. Drug reaction with eosinophilia and systemic symptoms (DRESS): Incidence, pathogenesis and management. Expert Opin Drug Saf. 2017;16(2):139-47. https://doi.org/10.1080/14740338.2017.1270940
   PMid:27936971
3. Gaffey CM, Chun B, Harvey JC, Manz HJ. Phenytoin-induced systemic granulomatous vasculitis. Arch Pathol Lab Med. 1986;110(2):131-5.
   PMid:3753844
4. Kardaun SH, Sekula P, Valeyrie-Allanore L, Liss Y, Chu CY, Creamer D, *et al*. Drug reaction with eosinophilia and systemic symptoms (DRESS): An original multisystem adverse drug reaction. Results from the prospective RegiSCAR study. Br J Dermatol. 2013;169(5):1071-80. https://doi.org/10.1111/bjd.12501
   PMid:23855313
5. Mizukawa Y, Hirahara K, Kano Y, Shiohara T. Drug-induced hypersensitivity syndrome/drug reaction with eosinophilia and systemic symptoms severity score: A useful tool for assessing disease severity and predicting fatal cytomegalovirus disease. J Am Acad Dermatol. 2019;80(3):670-8.e2. https://doi.org/10.1016/j.jaad.2018.08.052
   PMid:30240780
6. Shalom R, Rimbroth S, Rozenman D, Markel A. Allopurinol-induced recurrent DRESS syndrome: Pathophysiology and treatment. Ren Fail. 2008;30(3):327-9. https://doi.org/10.1080/08860220701861045
   PMid:18350453
7. Hama N, Abe R, Gibson A, Phillips EJ. Drug-induced hypersensitivity syndrome (DIHS)/drug reaction with eosinophilia and systemic symptoms (DRESS): Clinical features and pathogenesis. J Allergy Clin Immunol Pract. 2022;10(5):1155-67.e5. https://doi.org/10.1016/j.jaip.2022.02.004
   PMid:35176506
8. Ben m'rad M, Leclerc-Mercier S, Blanche P, Franck N, Rozenberg F, Fulla Y, *et al*. Drug-induced hypersensitivity syndrome: Clinical and biologic disease patterns in 24 patients. Medicine (Baltimore). 2009;88(3):131-40. https://doi.org/10.1097/MD.0b013e3181a4d1a1
   PMid:19440116
9. Kleier RS, Breneman DL, Boiko S. Generalized pustulation as a manifestation of the anticonvulsant hypersensitivity syndrome. Arch Dermatol. 1991;127(9):1361-4.
   PMid:1832535
10. Lee HY, Tay LK, Thirumoorthy T, Pang SM. Cutaneous adverse drug reactions in hospitalised patients. Singapore Med J. 2010;51(10):767-74.
    PMid:21103811
11. Shiohara T, Inaoka M, Kano Y. Drug-induced hypersensitivity syndrome (DIHS): A reaction induced by a complex interplay among herpesviruses and antiviral and antidrug immune responses. Allergol Int. 2006;56(1):1-8. https://doi.org/10.2332/allergolint.55.1
    PMid:17075280
12. Hansel K, Bellini V, Bianchi L, Brozzi J, Stingeni L. Drug reaction with eosinophilia and systemic symptoms from ceftriaxone confirmed by positive patch test: An immunohistochemical study. J Allergy Clin Immunol Pract. 2017;5(3):808-10. https://doi.org/10.1016/j.jaip.2016.10.009
    PMid:27923648
13. Shiohara T, Mizukawa Y. Drug-induced hypersensitivity syndrome (DiHS)/drug reaction with eosinophilia and systemic symptoms (DRESS): An update in 2019. Allergol Int. 2019;68(3):301-8. https://doi.org/10.1016/j.alit.2019.03.006
    PMid:31000444
14. Tohyama M, Hashimoto K, Yasukawa M, Kimura H, Horikawa T, Nakajima K, *et al*. Association of human herpesvirus 6 reactivation with the flaring and severity of drug-induced hypersensitivity syndrome. Br J Dermatol. 2007;157(5):934-40. https://doi.org/10.1111/j.1365-2133.2007.08167.x
    PMid:17854362
15. Sekiguchi A, Kashiwagi T, Ishida-Yamamoto A, Takahashi H, Hashimoto Y, Kimura H, *et al*. Drug-induced hypersensitivity syndrome due to mexiletine associated with human herpes virus 6 and cytomegalovirus reactivation. J Dermatol. 2005;32(4):278-81. https://doi.org/10.1111/j.1346-8138.2005.tb00762.x
    PMid:15863850
16. Skowron F, Bensaid B, Balme B, Depaepe L, Kanitakis J, Nosbaum A, *et al*. Drug reaction with eosinophilia and systemic symptoms (DRESS): Clinicopathological study of 45 cases. J Eur Acad Dermatol Venereol. 2015;29(11):2199-205. https://doi.org/10.1111/jdv.13212
    PMid:26354734
17. Descamps V, Valance A, Edlinger C, Fillet AM, Grossin M, Lebrun-Vignes B, *et al*. Association of human herpesvirus 6 infection with drug reaction with eosinophilia and systemic symptoms. Arch Dermatol. 2001;137(3):301-4.
    PMid:11255328
18. Shiohara T, Ushigome Y, Kano Y, Takahashi R. Crucial role of viral reactivation in the development of severe drug eruptions: A comprehensive review. Clin Rev Allergy Immunol. 2015;49:192-202. https://doi.org/10.1007/s12016-014-8421-3
    PMid:24736996
19. Niu J, Jia Q, Ni Q, Yang Y, Chen G, Yang X, *et al*. Association of CD8(+) T lymphocyte repertoire spreading with the severity of DRESS syndrome. Sci Rep. 2015;6(1):9913. https://doi.org/10.1038/srep09913
    PMid:25905582
20. Cacoub P, Musette P, Descamps V, Meyer O, Speirs C, Finzi L, *et al*. The DRESS syndrome: A literature review. Am J Med. 2011;124(7):588-97. https://doi.org/10.1016/j.amjmed.2011.01.017
    PMid:21592453
21. Husain Z, Reddy BY, Schwartz RA. DRESS syndrome: Part I. Clinical perspectives. J Am Acad Dermatol. 2013;68(5):693.e1-14; quiz 706-8. https://doi.org/10.1016/j.jaad.2013.01.033
    PMid:23602182
22. Markel A. Allopurinol-induced DRESS syndrome. IMAJ-RAMAT GAN. 2005;7(10):656-60.
    PMid:16259349
23. Yaylacı S, Demir MV, Temiz T, Tamer A, Uslan MI. Allopurinol-induced DRESS syndrome. Indian J Pharmacol. 2012;44(3):412. https://doi.org/10.4103/0253-7613.96351
    PMid:22701258
24. Thankachen J, Agarwal V. Challenges in diagnosis, management, and treatment of allopurinol-induced DRESS syndrome: Case report and literature review. Am J Ther. 2015;22(3):e77-83. https://doi.org/10.1097/MJT.0000000000000037
    PMid:24451301
25. Picard D, Janela B, Descamps V, D'Incan M, Courville P, Jacquot S, *et al*. Drug reaction with eosinophilia and systemic symptoms (DRESS): A multiorgan antiviral T cell response.

Sci Transl Med. 2010;2(46):46ra62. https://doi.org/10.1126/scitranslmed.3001116

PMid:20739682

26. Somkrua R, Eickman EE, Saokaew S, Lohitnavy M, Chaiyakunapruk N. Association of HLA-B*5801 allele and allopurinol-induced Stevens Johnson syndrome and toxic epidermal necrolysis: A systematic review and meta-analysis. BMC Med Genet. 2011;12:118. https://doi.org/10.1186/1471-2350-12-118

PMid:21906289

27. Mardivirin L, Valeyrie-Allanore L, Branlant-Redon E, Beneton N, Jidar K, Barbaud A, *et al*. Amoxicillin-induced flare in patients with DRESS (drug reaction with eosinophilia and systemic symptoms): Report of seven cases and demonstration of a direct effect of amoxicillin on human herpesvirus 6 replication *in vitro*. Eur J Dermatol. 2010;20(1):68-73. https://doi.org/10.1684/ejd.2010.0821

PMid:19822481