Scientific Foundation SPIROSKI, Skopje, Republic of North Macedonia
South East European Journal of Immunology. 2023 Jul 20; 6(1):39-44.
https://doi.org/10.3889/seejim.2023.6039
eISSN: 1857-9388
Category: *Original article*
Section: *Allergology*

OPEN ACCESS

Chronic Rhinosinusitis with Polyps and Comorbid Asthma: Results of Reslizumab Treatment

Natalia Boiko*, Irina Stagnieva, Olga Lodochkina

Department of ENT, Rostov State Medical University, Rostov-on-Don, Rostov Region, Russian Federation

Edited by: Slavica Hristomanova-Mitkovska
Citation: Boiko N, Stagnieva I, Lodochkina O. Chronic Rhinosinusitis with Polyps and Comorbid Asthma: Results of Reslizumab Treatment. SEEJImmunol. 2023 Jul 20; 6(1):39-44. https://doi.org/10.3889/seejim.2023.6039
Keywords: Asthma; Chronic rhinosinusitis with nasal polyps; Reslizumab
***Correspondence:** Natalia Boiko, Department of ENT, Rostov State Medical University, Rostov-on-Don, Rostov Region, Russian Federation. E-mail: nvboiko@gmail.com
Received: 04-May-2023
Revised: 22-May-2023
Accepted: 06-Jul-2023
Copyright: © 2023 Natalia Boiko, Irina Stagnieva, Olga Lodochkina
Funding: This research did not receive any financial support
Competing Interests: The authors have declared that no competing interests exist
Open Access: This is an open-access article distributed under the terms of the Creative Commons Attribution-NonCommercial 4.0 International License (CC BY-NC 4.0)

Abstract

BACKGROUND: Chronic rhinosinusitis with nasal polyps (CRSwNP) and asthma are comorbid, mutually burdening, difficult-to-treat diseases. The presence of a correlation between the severity of the course of CRSwNP and eosinophilic asthma, the proximity of the endotypes of these diseases, and the success in the application of humanized monoclonal antibodies for the treatment of severe asthma explain the interest in the study of the possibility of using this group of medications in patients with CRSwNP.

AIM: The present study purposes to evaluate changes in the severity of CRS symptoms in patients with comorbid asthma during reslizumab treatment. The clinical effect of the treatment, the dynamics of subjective and objective characteristics of (CRSwNP) and asthma symptoms, indicators of general and local eosinophilia have been analyzed.

MATERIALS AND METHODS: The study involved 18 patients with severe eosinophilic asthma, treated with reslizumab. Research protocol: the first examination conducted before reslizumab treatment included an assessment of clinical symptoms using Sino-nasal outcome test-22 and asthma control test, endoscopic examination of the nasal cavity, computed tomography of the paranasal sinuses, rhinocytogram, determination of the content of eosinophils and eosinophil cation protein in the blood, spirometry. Evaluation of the results of treatment was carried out after 6 injections of reslizumab at a dose of 3 mg/kg 1 time every 4 weeks. The obtained data were processed by means of the "Statistica 12.0" program (StatSoft, USA). The differences in the indicators were considered statistically significant at $p < 0.05$.

RESULTS: After 6 injections of reslizumab both a noticeable improvement in asthma control and a decrease in the severity of the nasal symptoms were noted. A more evident effect in diminution of asthma symptoms due to the use of reslizumab was obtained in patients with severe eosinophilic asthma with CRSwNP compared with cases without polyps.

CONCLUSION: Treatment with reslizumab in patients with eosinophilic asthma and concomitant CRS with polyps and eosinophilic CRS leads not only to improved control of asthma symptoms but also to significant regression of nasal symptoms.

Introduction

Chronic rhinosinusitis (CRS) and asthma are inflammatory disorders of the airway that often co-exist. Asthma and some CRS subtypes are mediated by similar pathophysiologic mechanisms that involve type 2 inflammatory pathways through eosinophils and pro-eosinophilic cytokine mediators such as interleukin-5 (IL-5), IL-4, IL-13, and immunoglobulin E (IgE).

Transition from standardization to personalized treatment have led to the separation of such heterogeneous diseases as asthma and CRS into clinically similar groups called phenotypes.

From the clinical viewpoint CRS is commonly divided into two phenotype-based groups on the presence CRS with nasal polyps (CRSwNP) or absence of nasal polyps (CRSsNP). The first phenotype is associated with eosinophilic or Th2-polarized inflammation while the second - with neutrophilic or non-Th2-polarized one [1]. In 80–90% of patients suffering from CRS with polyps, a significant systemic and local eosinophilia is identified, along with an increase in the local level of Th2-dependent cytokines, such as IL-4, IL-5, IL-9, IL-13, IL-25, IL-33, increased expression of the receptors to IL-5 and local production of IgE, while the key mediator of eosinophilic inflammation is IL-5, which provides activation, chemotaxis and survival of eosinophils [2].

In the international consensus document EPOS 2020 [3], a new classification was proposed, according to which CRS is divided into primary and secondary, and each of these groups is divided, depending on the prevalence of the process, into localized and diffuse forms of CRS. Diffuse primary CRS is divided by the nature of the dominant inflammatory endotype into 2 groups: Type 2 (Th2 type) and non-type 2 (non-Th2 type). The Th2 type

group includes CRSwNP/eosinophilic rhinosinusitis, allergic fungal rhinosinusitis and central compartment allergic disease; the non-Th2 type group includes non-eosinophilic rhinosinusitis.

CRS with polyps is often combined with asthma. In patients with asthma, CRSwNP is detected in 7–16% of cases and more than 80% have X-ray signs of inflammatory diseases of the paranasal sinuses [4], [5], while in 26–48% of patients with CRSwNP the concomitant disease is asthma [6], [7]. These comorbid diseases mutually burden each other: On the one hand, asthma in patients with CRSwNP is much more severe [8], [9], on the other hand, this group of patients is characterized by more frequent recurrence of polyps after surgical treatment [10].

Asthma is also a group of clinical variants that differ in pathophysiological parameters, the type and severity of inflammation, the response to corticosteroid therapy, and many other factors. Currently, there are several phenotypes of asthma: Allergic, non-allergic (eosinophilic), asthma with permanent obstruction, infection dependent, asthma with late onset, asthma associated with obesity [11], [12]. Inflammation in eosinophilic asthma has similar features to that in patients having CRSwNP: An increased content of eosinophils in the mucosa, in sputum and in blood, Th2-type of inflammatory reaction with hyperproduction of IL-5 and eosinophil cationic protein (ECP) [13].

In the last decade, a new promising direction has appeared in the treatment of asthma - targeted therapy with humanized monoclonal antibodies (biologics) [14], [15].

The correlation between the severity of CRSwNP and eosinophilic asthma, the proximity of the endotypes of these diseases [16] along with the successful use of biologics for the treatment of severe asthma [14] explain the interest in the research of the possibility of using this group of drugs in patients with CRSwNP [17], [18], [19], [20].

Aims

The aim of the research was to study the dynamics of nasal symptoms in patients with CRSwNP combined with asthma during reslizumab treatment.

Reslizumab is a humanized monoclonal antibody with a high affinity for IL-5. Reslizumab specifically binds to IL-5, causing a restriction of differentiation, chemotaxis, activation and survival of eosinophils [13], [21], thereby reducing the level of eosinophilic inflammation and remodeling of the respiratory tract.

Materials and Methods

A total of 18 patients aged 29–59 years undergoing treatment with reslizumab for severe eosinophilic asthma have been examined during the research. The study was conducted in pulmonological departments of multidisciplinary medical institutions in Rostov-on-Don, Russia (Regional clinical and diagnostic center and Regional clinical hospital) from May 2019 to May 2021.

Selection criteria for reslizumab treatment. Patients over 18 years old with a confirmed diagnosis of eosinophilic asthma, eosinophilia of blood and sputum, lack of adequate control of asthma symptoms or exacerbations more than once a year, despite standard treatment relevant to stages 4–5 according to 2019 GINA classification [22].

Reslizumab was injected intravenously at a dose of 3 mg/1 kg once in every 4 weeks as a supplement to the baseline therapy of asthma (medium and high doses of inhaled corticosteroids in combination with long-acting β2-agonists), which patients had previously received.

Patients' examination before the start of the treatment and after 6 injections of reslizumab included endoscopy of the nasal cavity with determination of the total polyp score (TPS), computed tomography (CT) of the paranasal sinuses, rhinocytogram, determination of the content of eosinophils in the blood and ECP in the blood serum, allergological examination through the Immuno CAP method and spirometry. The TPS was evaluated in points according to the standard scheme: 0 - no polyps, 1 - small polyps in the middle meatus not reaching below the inferior border of the middle concha; 2 - polyps reaching below the lower border of the middle turbinate; 3 - large polyps reaching the lower border of the inferior turbinate or polyps medial to the middle concha; and 4 - large polyps causing complete obstruction of the inferior meatus.

The TPS index was determined as the sum of the right and left nostril scores. The CT images of the paranasal sinuses and the ostiomeatal complex were evaluated on the Lund-Mackay score.

The rhinocytogram was carried out through the method of liquid cytology with the sample staining according to the Papanicolaou method (Pap test). Special cytobrushes placed in a bottle with a transport medium were used for collecting nasal mucus. The level of systemic eosinophilia was assessed according to the cell content in 1 μL. The cell content was calculated by the formula: the number of leukocytes 10^9 × the number of eosinophils in percent ×10.

To analyze the dynamics of clinical symptoms, the sinonasal outcome test-22 (SNOT-22) questionnaire and the asthma control test (ACT) were used [23], [24].

The effectiveness of asthma symptom control was evaluated by a pulmonologist by the reducing frequency of asthma exacerbations (including those exacerbations requiring the use of systemic corticosteroids), improvement of the quality of life, spirometry, and ACT results.

Statistical analysis of the results was carried out via “Statistica 12.0” program (StatSoft, USA). The normality of the distribution of values in the sample was checked with Shapiro-Wilk test.

The values in the sample were represented as the average sample value with its errors, median, interquartile range. The statistical significance of the difference in the dynamics of indicators was evaluated using the Wilcoxon test for dependent samples.

Results

During the initial examination, subjective symptoms of nasal and paranasal sinus pathology were revealed in patients: Watery (more often) or thick nasal discharge (18/18), persistent (12/18) or intermittent nasal obstruction (6/18), postnasal congestion (12/18), decreased sense of smell (14/18).

The duration of the disease ranged from 2 to 17 years, and in 7 patients the disease began with the appearance of symptoms of rhinitis in the form of abundant watery discharge from the nose and sneezing attacks, however multiple allergological examination did not reveal any signs of sensitization. Subsequently, those patients had nasal congestion, followed by asthma symptoms and nasal polyps.

During the endoscopic examination, nasal polyps were found in 15 patients with a TPS index from 2 to 5. CT of the paranasal sinuses in this group of patients showed signs of involvement to all sinuses, with a Lund-Mackay index from 11 to 20.

In 3 patients, no polyps were found in the nasal cavity, there was swelling of the nasal mucosa during endoscopy and thickening of the paranasal sinus mucosa on CT. Those patients were observed for a long time with a diagnosis of allergic rhinitis. However, the detected eosinophilia of the rhinocytogram (up to 75%), a significant increase of ECP in blood and two-fold negative results of the allergic tests allowed us to diagnose those patients with non-allergic rhinitis with eosinophils (NARES). Here it should be mentioned that in those patients, a more evident effect of reslizumab was noted in the regression of nasal symptoms according to SNOT-22, but the indicators of ACT and forced expiratory volume in 1 s (FEV1) did not improve significantly.

The dynamics of the studied indicators is presented in Table 1.

Table 1: Changes in the main indicators characterizing the effectiveness of reslizumab treatment

Indicator	Statistical value	Before treatment	After treatment	p*-value
SNOT-22	M ± m	68.6 ± 4.0	41.0 ± 5.5	0.0004
	Me (25–75)	78.0 (62–81)	39.0 (29–49)	
ACT	M ± m	7.9 ± 0.7	18.6 ± 1.4	0.0002
	Me (25–75)	7.0 (6–8)	22.0 (16–22)	
FEV1	M ± m	59.1 ± 5.4	70.7 ± 6.6	0.0279
	Me (25–75)	67.0 (42–80)	76.0 (49–89)	
TPS	M ± m	2.7 ± 0.5	1.8 ± 0.4	0.06
	Me (25–75)	2.0 (2–5)	1.0 (0–4)	
Lund-Mackay score	M ± m	13.1 ± 1.6	9.8 ± 1.9	0.0303
	Me (25–75)	16.0 (11–19)	7.0 (5–12)	
Eosinophils: The number of cells in 1 mL (%)	M ± m	1387.1 ± 176.8	99.1 ± 8.6	0.0002
	Me (25–75)	1194 (738–2170)	119.0 (61.6–127)	
ECP in ng/mL	M ± m	63.7 ± 10.6	12.7 ± 1.1	0.0002

*The confidence probability of differences in the dynamics of observation, the Wilcoxon signed-rank test was used, M ± m is the average sample value and the error of the average value, Me stands for the median, (25–75) is the interquartile range, statistically significant differences are highlighted in bold, SNOT-22: Sino-nasal outcome test-22, FEV1: Forced expiratory volume in 1 s.

A significant decrease in blood eosinophilia was registered in all patients after the first administration of reslizumab and the low level of eosinophils remained throughout the entire follow-up period, despite some fluctuations in this parameter.

Improvement of nasal breathing was noted in 16 out of 18 patients, what was displayed in the dynamics of SNOT-22. Disappearance of hyposmia after the first injection of the drug was noted by 8 patients, in 4 more patients hyposmia disappeared 2 months after the start of the treatment. The positive dynamics was confirmed by endoscopy data (reduction of TPS) and CT of the paranasal sinuses.

In 12 out of 18 patients, a decrease in the severity of asthma symptoms was noted: A significant improvement in the FEV1 index, improved exercise tolerance, reduced need for salbutamol or other short-acting b2 agonists, improved quality of sleep and emotional background. Along with that there were no exacerbations of asthma registered during the entire follow-up period. An increase in the AST index of more than 20 was observed in 12 out of 18 patients, which indicates that control over asthma symptoms had been achieved, and moreover all those patients were diagnosed with CRSwNP. The absence of subjective and objective improvement was registered in 1 patient with aspirin-exacerbated respiratory disease (AERD).

To illustrate the results described above, we present an extract from the medical history of patient X, who showed the most evident effect of the reslizumab treatment.

Patient X., 41 y. o., suffers from severe persistent controlled bronchial asthma, GINA step 5, CRSwNP. The disease began at the age of 27 with attacks of rhinorrhea and sneezing. The patient noted abundant watery discharge from the nose, not accompanied by nasal congestion and itching in the nose, which lasted for 11 years. Repeatedly conducted tests did not reveal any sensitization. At the age of 38, a paroxysmal cough appeared, more often at night. The pulmonologist diagnosed asthma, started treatment with inhaled glucocorticosteroids in combination with long-acting β2-agonists. Meanwhile,

the patient noted increasing difficulty of nasal breathing, progressive hyposmia; nasal topical corticosteroids were added to the course of treatment, which he used irregularly. After 2 years, while undergoing the general therapy for asthma, he experienced several episodes of eosinophilic pneumonia. Asthma exacerbations requiring hospitalization became more frequent up to 3–4 times a year, a need for treatment with systemic corticosteroids (in courses) became necessary. Considering the severe course of asthma, the patient was selected for the reslizumab treatment group.

While being examined, the patient complains of nasal obstruction, lack of smell, postnasal congestion (64 points according to the SNOT-22). Endoscopic examination revealed swelling of the nasal mucosa, the presence of medium-sized polyps (TPS 5). The results of CT of the paranasal sinuses on the Lund-Mackay score: R10L10T20.

The initial number of eosinophils in the blood is 2487 cl/mcl, in the rhinocytogram - 36%, the ECP of the blood equals 168 ng/mL. The patient received 6 injections of reslizumab at a dose of 3.0 mg/kg with an interval of 4 weeks. The evaluation of the treatment results was carried out 6 months after the start of treatment.

After the first administration of reslizumab, the patient noted the disappearance of hyposmia and rhinorrhea and improvement of nasal breathing (29 points in the SNOT control study). During endoscopic examination of the nasal cavity, there are no polyps on the right, on the left they are identified in the middle nasal meatus, they do not go beyond the lower edge of the middle nasal concha - TPS 1 (Figure 1).

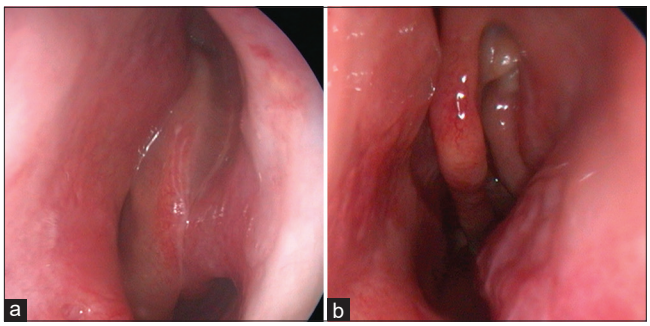

Figure 1: Endoscopy of the left half of the patient X's nose: (a) before the treatment, (b) 6 months after the treatment with reslizumab

CT revealed a significant improvement on the Lund-Mackay score: R2L3T5 (Figure 2). The number of eosinophils in the blood decreased to 136.4 cl/mL, in the rhinocytogram-to 17%, the ECP of the blood was 20.1 ng/mL.

According to the pulmonological study of the changes in AST from 7 to 22 points, a significant improvement in lung function was registered (FEV1 86% and 103%, respectively). During the follow-up period of 6 months, there was no need for systemic corticosteroid therapy.

Discussion

In our research we have evaluated the dynamics of nasal symptoms when using reslizumab in patients with severe eosinophilic asthma. The presence of CRSwNP was detected in 15 of the 18 studied patients, 3 patients had symptoms of chronic rhinitis as a manifestation of NARES. Changes in the CT were present in 100% of cases.

Along with a noticeable improvement in asthma control, which was confirmed by studies of lung function, patients showed clinical, endoscopic, radiological signs of a decrease in the severity of nasal symptoms. The improvement in the quality of life was confirmed by the results of SNOT-22, which revealed a decrease in symptoms such as rhinorrhea, nasal obstruction, hyposmia and sleep disorders.

The data of endoscopic examination revealed a reduction of polyps in 1 out of 15 patients, which indicates the possibility of reverse development of remodeling of the nasal mucosa during targeted therapy. No positive dynamics of nasal symptoms and the course of asthma was noticed in one patient with AERD. In the case of another patient control over asthma symptoms was achieved (an increase in AST from 8 to 22 and FEV1 from 86% to 106%), however the growth of polyps continued (TPS increased from 2 to 5).

The improvements observed in patients with CRSwNP and comorbid asthma testify that reslizumab affects eosinophilic inflammation of both the lower and upper respiratory tracts. The results of our clinical study coincide with the conclusions of earlier observations [18], [25].

In the literature there is certain evidence that the presence of polyps in patients with eosinophilic asthma allows predicting a positive result in the treatment with reslizumab. Thus, Weinstein *et al*. [5] performed a retrospective analysis of the patient-reported medical histories of 953 patients with inadequately controlled asthma treated with reslizumab for 52 weeks. 150 patients (16%) had self-reported CRSwNP, endoscopic examination of the nasal cavity and CT of the paranasal sinuses were not conducted. Despite these serious limitations, the authors proved that patients with CRSwNP were highly responsive to treatment with reslizumab. We also noted more significant positive changes in AST and spirometry indicators in patients having CRS with nasal polyps.

Patients without nasal polyps with recurrent symptoms of rhinitis (rhinorrhea, sneezing, nasal congestion) are of particular interest. These patients were observed for a long time with a diagnosis of allergic rhinitis. However, the detected eosinophilia of the rhinocytogram (up to 75%), an increase in the ECP content in the blood and at least twice the negative results of the allergic tests

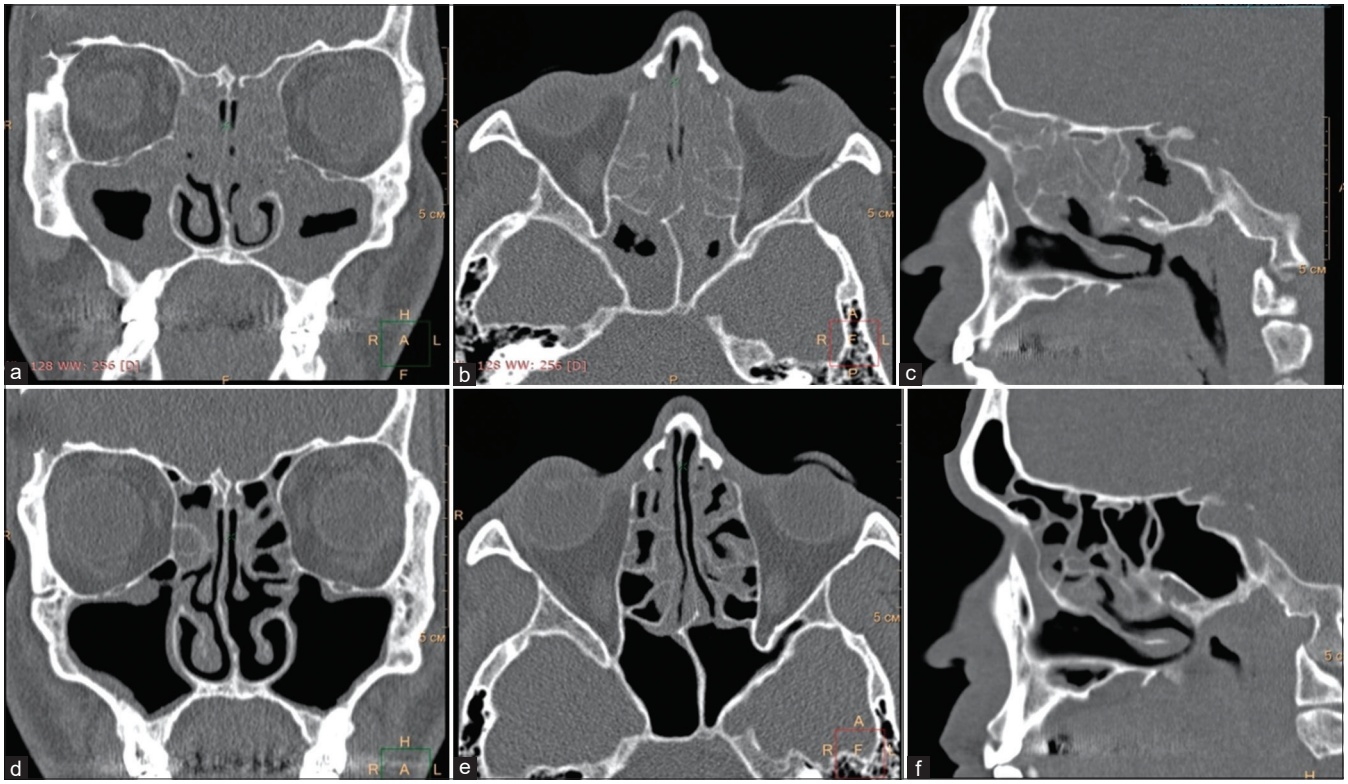

Figure 2: SCT of the paranasal sinuses of patient X: (a-c) before the treatment, (d-f) 6 months after the start of the treatment with reslizumab

allowed us to diagnose these patients with NARES. In the group of patients with CRS with nasal polyps, it was possible to detect the anamnestic presence of similar symptoms at the beginning of the disease. These results confirm the previously suggested assumption that NARES may be a predictor of the development of AERD, non-IgE-related asthma and nasal polyps [26].

The study of the cytokine profile of inflammation clarifies the pathogenetic features of various phenotypes of the disease, which determines the direction of targeted therapy [6], [27], [28]. However, the studies of the content of cytokines in the tissues of polyps and the nasal mucosa [6] are currently beyond the scope of practical health care. Today the prediction criterion for the effectiveness of reslizumab is an increase in the number of eosinophils in the blood of more than 400 cells/mL. Further studies of the use of monoclonal antibodies should reveal additional clinical criteria for the selection of patients with CRS with polyps for the use of this group of drugs.

Conclusion

Reslizumab treatment of patients with eosinophilic asthma and concomitant CRSwNP and chronic NARES leads not only to improved control of asthma symptoms, but also to a significant regression of nasal symptoms.

Clinical significance

Currently, the indications for the treatment of CRS with polyps have been registered in dupilumab, omalizumab, mepolizumab [29] (Reference). Studies of the effects of other biologics can not only expand their indications, but also identify possible advantages in the selection of drugs for the treatment of different types of CRS.

References

1. Akdis CA, Bachert C, Cingi C, Dykewicz MS, Hellings PW, Naclerio RM, *et al*. Endotypes and phenotypes of chronic rhinosinusitis: A PRACTALL document of the European Academy of Allergy and Clinical Immunology and the American Academy of Allergy, Asthma and Immunology. J Allergy Clin Immunol. 2013;131(6):1479-90. https://doi.org/10.1016/j.jaci.2013.02.036
   PMid:23587334
2. Tomassen P, Vandeplas G, Van Zele T, Cardell LO, Arebro J, Olze H, *et al*. Inflammatory endotypes of chronic rhinosinusitis based on cluster analysis of biomarkers. J Allergy Clin Immunol. 2016;137(5):1449-56.e4. https://doi.org/10.1016/j.jaci.2015.12.1324
   PMid:26949058
3. Fokkens WJ, Lund VJ, Hopkins C, Hellings PW, Kern R, Reitsma S, *et al*. European position paper on rhinosinusitis and nasal polyps 2020. Rhinology. 2020;58(Suppl 29):1-464. https://doi.org/10.4193/rhin20.600
   PMid:32077450
4. Bresciani M, Paradis L, Des Roches A, Vernhet H, Vachier I, Godard P, *et al*. Rhinosinusitis in severe asthma. J Allergy Clin Immunol. 2001;107(1):73-80. https://doi.org/10.1067/

mai.2001.111593
PMid:11149994

5. Weinstein SF, Katial RK, Bardin P, Korn S, McDonald M, Garin M, *et al*. Effects of reslizumab on asthma outcomes in a subgroup of eosinophilic asthma patients with self-reported chronic rhinosinusitis with nasal polyps. J Allergy Clin Immunol Pract. 2019;7(2):589-96.e3. https://doi.org/10.1016/j.jaip.2018.08.021
PMid:30193936
6. Promsopa C, Kansara S, Citardi MJ, Fakhri S, Porter P, Luong A. Prevalence of confirmed asthma varies in chronic rhinosinusitis subtypes. Int Forum Allergy Rhinol. 2016;6(4):373-7. https://doi.org/10.1002/alr.21674
PMid:26678021
7. Stevens WW, Schleimer RP, Kern RC. Chronic rhinosinusitis with nasal polyps. J Allergy Clin Immunol Pract. 2016;4(4):565-72. https://doi.org/10.1016/j.jaip.2016.04.012
PMid:27393770
8. Bachert C, Claeys SE, Tomassen P, van Zele T, Zhang N. Rhinosinusitis and asthma: A link for asthma severity. Curr Allergy Asthma Rep. 2010;10(3):194-201. https://doi.org/10.1007/s11882-010-0096-0
PMid:20424997
9. Huang CC, Wang CH, Fu CH, Huang CC, Chang PH, Chen IW, *et al*. The link between chronic rhinosinusitis and asthma: A questionnaire-based study. Medicine (Baltimore). 2016;95(31):e4294. https://doi.org/10.1097/md.0000000000004294
PMid:27495032
10. Van Zele T, Holtappels G, Gevaert P, Bachert C. Differences in initial immunoprofiles between recurrent and nonrecurrent chronic rhinosinusitis with nasal polyps. Am J Rhinol Allergy. 2014;28(3):192-8. https://doi.org/10.2500/ajra.2014.28.4033
PMid:24980230
11. Wenzel SE. Asthma phenotypes: The evolution from clinical to molecular approaches. Nat Med. 2012;18(5):716-25. https://doi.org/10.1038/nm.2678
PMid:22561835
12. Bateman ED, Hurd SS, Barnes PJ, Bousquet J, Drazen JM, FitzGerald M, *et al*. Global Strategy for Asthma Management and Prevention: GINA executive summary. Eur Respir J. 2008;31:143-78. https://doi.org/10.1183/09031936.00138707
13. Koennecke M, Klimek L, Mullol J, Gevaert P, Wollenderg B. Subtyping of polyposis nasi: Phenotypes, endotypes and comorbidities. Allergo J Int. 2018;27(2):56-65. https://doi.org/10.1007/s40629-017-0048-5
PMid:29564208
14. Corren J. New targeted therapies for uncontrolled asthma. J Allergy Clin Immunol Pract. 2019;7(5):1394-403. https://doi.org/10.1016/j.jaip.2019.03.022
PMid:31076057
15. De Filippo M, Votto M, Licari A, Pagella F, Benazzo M, Ciprandi G, *et al*. Novel therapeutic approaches targeting endotypes of severe airway disease. Expert Rev Respir Med. 2021;15(10):1303-16. https://doi.org/10.1080/17476348.2021.1937132
PMid:34056983
16. Wu D, Bleier BS, Li L, Zhan X, Zhang L, Wei Y, *et al*. Clinical phenotypes of nasal polyps and comorbid asthma based on cluster analysis of disease history. J Allergy Clin Immunol Pract. 2018;6(4):1297-305.e1 https://doi.org/10.1016/j.jaip.2017.09.020
PMid:29100865
17. Fokkens WJ, Lund V, Bachert C, Mullol J, Bousquet J, Canonica GW, *et al*. EUFOREA consensus on biologics for CRSwNP with or without asthma. Allergy. 2019;74(12):2312-9. https://doi.org/10.1111/all.13875
PMid:31090937
18. Kariyawasam HH, James LK, Gane SB. Dupilumab: Clinical efficacy of blocking IL-4/IL-13 signalling in chronic rhinosinusitis with nasal polyps. Drug Des Devel Ther. 2020;14:1757-69. https://doi.org/10.2147/dddt.s243053
PMid:32440101
19. Boiko NV, Lodochkina OE, Kit MM, Kuleshova VG, Nedashkovskaya NG. Impact of reslizumab on the course of chronic rhinosinusitis in patients with eosinophilic asthma. Vestn Otorinolaringol. 2021;86(2):43-8. https://doi.org/10.17116/otorino20218602143
PMid:33929151
20. Koski RR, Hill L, Taavola K. Efficacy and safety of biologics for chronic rhinosinusitis with nasal polyps. J Pharm Technol. 2022;38(5):289-96. https://doi.org/10.1177/87551225221105749
PMid:36046351
21. Legrand F, Klion AD. Biologic therapies targeting eosinophils: Current status and future prospects. J Allergy Clin Immunol Pract. 2015;3(2):167-74. https://doi.org/10.1016/j.jaip.2015.01.013
PMid:25754717
22. Reddel HK, FitzGerald JM, Bateman ED, Bacharier LB, Becker A, Brusselle G, *et al*. GINA 2019: A fundamental change in asthma management: Treatment of asthma with short-acting bronchodilators alone is no longer recommended for adults and adolescents. Eur Respir J. 2019;53(6):1901046. https://doi.org/10.1183/13993003.01046-2019
PMid:31249014
23. Gallo S, Russo F, Mozzanica F, Preti A, Bandi F, Costantino C, *et al*. Prognostic value of the Sinonasal Outcome Test 22 (SNOT-22) in chronic rhinosinusitis. Acta Otorhinolaryngol Ital. 2020;40(2):113-21. https://doi.org/10.14639/0392-100X-N0364
PMid:32469005
24. Matsunaga NY, Ribeiro MA, Saad IA, Morcillo AM, Ribeiro JD, Toro AA. Evaluation of quality of life according to asthma control and asthma severity in children and adolescents. J Bras Pneumol. 2015;41(6):502-8. https://doi.org/10.1590/S1806-37562015000000186
PMid:26785958
25. Máspero J. Reslizumab in the treatment of inadequately controlled asthma in adults and adolescents with elevated blood eosinophils: Clinical trial evidence and future prospects. Ther Adv Respir Dis. 2017;11(8):311-25. https://doi.org/10.1177/1753465817717134
PMid:28683596
26. Settipane RA, Lieberman P. Update on nonallergic rhinitis. Ann Allergy Asthma Immunol. 2001;86(5):494-507; quiz 507-8. https://doi.org/10.1016/s1081-1206(10)62896-7
PMid:11379801
27. Gevaert P, Lang-Loidolt D, Lackner A, Stammberger H, Staudinger H, Van Zele T, *et al*. Nasal IL-5 levels determine the response to anti-IL-5 treatment in patients with nasal polyps. J Allergy Clin Immunol. 2006;118(5):1133-41. https://doi.org/10.1016/j.jaci.2006.05.031
PMid:17088140
28. Boiko NV, Kim AS, Stagnieva IV, Simbirtsev AS. Proinflammatory cytokine content in the saliva of children suffering from chronic tonsillitis. Vestn Otorinolaringol. 2019;84(3):26-31. https://doi.org/10.17116/otorino20198403126
PMid:31486423
29. Wu Q, Zhang Y, Kong W, Wang X, Yuan L, Zheng R, *et al*. Which is the best biologic for nasal polyps: Dupilumab, omalizumab, or mepolizumab? A network meta-analysis. Int Arch Allergy Immunol. 2022;183(3):279-88. https://doi.org/10.1159/000519228
PMid:34607329